

Surveying the Expression of CDH1 and EGFR Genes in Patients with Anthracosis and Its Relationship with Lung Carcinoma

Zahra Izadian¹, Naghmeh Bahrami², Tahereh Naji³, Abdolreza Mohamadnia^{4,5}

¹Department of Molecular and Cellular Sciences, Faculty of Advanced Sciences and Technology, Pharmaceutical Sciences Branch, Islamic Azad University, Tehran, Iran. ²Craniofacial Research Center, Tehran University of Medical Sciences, Tehran, Iran; Department of Oral and Maxillofacial Surgery, School of Dentistry, Tehran University of Medical Sciences, Tehran, Iran. ³Department of Basic Sciences, Faculty of Pharmacy, Pharmaceutical Sciences Branch, Islamic Azad University, Tehran, Iran. ⁴Virology Research Center, National Research Institute of Tuberculosis and Lung Diseases (NRITLD), Shahid Beheshti University of Medical Sciences, Tehran, Iran. ⁵Department of Biotechnology, School of Advanced Technologies in Medicine, Shahid Beheshti University of Medical Sciences, Tehran, Iran.

Abstract

Introduction: Anthracosis is known as the black lung disease and studies have shown relationships between the disease and lung carcinoma. In addition, the expression of CDH1 and EGFR genes can be used as the prognostic of anthracosis. The present study surveys the expression of CDH1 and EGFR genes in anthracosis patients and its relationship with non-small cells lung carcinoma. **Methodology:** Thirty anthracosis patients diagnosed by a specialist participated in the study. The subjects were asked to sign an informed letter of consent and then, to examine the expression of CDH1 and EGFR genes through real-time PCR, tissue samples were collected. Afterward, the relationship of expression of the biomarkers with tumor staging and cancer progress was examined. **Results:** Mean age of the patients was 48±10.5 years. As the reference gene, 18sRNA was adopted and comparison of mean CTs at the center and edges of lesions showed no significant difference. As to CDH1 gene at the center of lesions, 12 cases out of 30 were positive, which indicates 40% sensitivity; while at the edges, 20 cases out of 30 were positive. Comparison of the positive rates of CDH1 gene at the center and edges of the lesions indicated a significant difference (P-value<0.001). Moreover and with regard to EGFR gene at the center of lesions, 19 cases out of 30 were positive (sensitivity = 63.3%) and five cases out of 30 were positive at the edges of lesions (control). There was also a significant difference between the positive cases of EGFR gene at the center and edges of the lesions (P-value<0.001). Clearly, the positive cases of CDH1 at the edges were higher than that at the center, while in the case of EGFR gene, positive cases at the center were higher than that at the edges. It is notable that to obtain results with higher accuracy entails increasing the sensitivity level. Following similar studies and to have higher accuracy, the experiments were carried out with three iterations. **Conclusion:** In general, the results indicated a sort of relationship between anthracosis and lung carcinoma. To prove such relationship on a more solid ground, more studies with larger number of subjects are needed.

Keywords: Anthracosis- lung carcinoma- gene expression- CDH1 Biomarker- EGFR biomarker

Asian Pac J Cancer Care, 2 (4), 79-83

Submission Date: 08/26/2017 Acceptance Date: 10/13/2017

Introduction

Anthracosis is the pneumoconiosis caused by exposure to coal dust [1]. The term “anthracosis” refers to coal particles and other black pigments of which carbon is the main element [2]. Coal particles, mostly in the coal mine workers and to a less extent in city dweller,

are found in the background of vocational and air pollution diseases as sediment at mucosa and submucosa; and under bronchoscopy, they appear as black lesions with normal or deformed bronchus with high fragility [2].

In addition to coal mine workers, the disease is found among workers in the industries related to coal [2]. In fact, occupational exposure to carbon, silicon dioxide,

Corresponding Author:

Dr. Abdolreza Mohamadnia

Virology Research Center, National Research Institute of Tuberculosis and Lung Diseases (NRITLD), Shahid Beheshti University of Medical Sciences, Tehran, Iran.

Department of Biotechnology, School of Advanced Technologies in Medicine, Shahid Beheshti University of Medical Sciences, Tehran, Iran.

Email: mohamadnia.ar@gmail.com

and quartz at work are the known causes of pulmonary anthracosis; although, there are cases without any pertinent occupation history as well [3]. In other words, anthracosis is an outcome of aggregation of carbon in the lungs after long and frequent exposure to air pollution and inhaling smock and coal dust [4]. In addition to the lungs, there are reports of anthracosis in the liver, spleen, and esophagus; the latter case should be considered as a serious disease as it demonstrates malignant melanoma [5]. In some cases, an anthracosis case is misdiagnosed as tuberculosis, lung carcinoma, or pneumonia [6].

Cytology studies on pulmonary tissues have shown that inter-bronchus anthracosis and lymphadenopathy mediastinum are concurrent with the early endocardium. Thereby, there is a probably significant relationship between anthracosis and lung carcinoma [7].

Lung carcinoma is the most common type of cancer in men [8, 9] and more than 80% of the patients die during the first five years after diagnosis [10-13].

CDH1 gene encodes E-Cadherin protein [14] and it is a tumor suppressor gene with a key role in preserving cellular adhesion and stable connections in normal tissues through the expression of the Cadherin1 protein. In addition, the gene keeps epithelium cells in their normal layer and arrangement [15].

The role of E-Cadherin in signaling indicates that the molecule can demonstrate different functions so that it can regulate the cell response to the external signals received by cell. Therefore, it can regulate migration, proliferation, apoptosis, and cell differentiation [16].

Failure of CDH1 function facilitates the progress of cancer via the increase of proliferation, invasion, and metastasis [15]. The decrease of E-cadherin expression is a main molecular event effective on the failure of inter-cell adhesion system, cancer invasion, and metastasis [16]. Epidermal growth factor receptor (EGFR) receives epidermal growth factor family (EGF family) from extracellular protein ligands [17, 18]. By attaching to epidermal growth factors (EGF) and transforming growth factor (TGF), EGFR induces cellular proliferation. Activation of EGFR messaging path in cancerous cells leads to cellular proliferation, angiogenesis, metastasis, and a decrease of apoptosis [19]. EGFR is highly expressed in a variety of malignancies like head and neck, colorectal, lung, breast, and bladder [20].

The present study is an attempt to survey and compare the expression of CHD1 and EGFR genes at the center and edges of the black lesions in anthracosis patients and examine the relationship between anthracosis and lung carcinoma.

Materials and Methods

To examine the expression of CDH1 and EGFR genes, 30 patients in Masih Daneshvari Hospital-Tehran with confirmed cases of anthracosis (based on physical examinations by a specialist) who had received no treatment intervention at the time of the study were elected. After examinations by the specialist, the candidates interested in participation filled out a letter

of consent. Afterward, tissue samples from the center the lesions and the unaffected tissue around the lesions (as a control sample) were collected by the specialist in bronchoscopy ward.

RNA extraction

The extraction was done using Cinna pure RNA kit (cat.NO:PR891620-S). About 25-50mg fresh tissue was placed on a plate and transferred to RNAase-DNase free micro-tubes -1.5ml. Afterward, the samples were crushed to obtain a homogenized tissue and the extraction steps were implemented as per the instruction. The nano-drop device was used to evaluate the quality of the extracted RNA.

cDNA preparation

Viva 2-steps RT-PCR Kit (Cat no.RTPL12) was used to extract cDNA from mRNA. The kit is featured with high sensitivity and capacity for the proliferation of any type of DNA out of RNA. Afterward, specific polymers were designed in Allele ID6 and ordered for preparation.

RT PCR reaction

CinnaGree qPCR Mix, 2X and Sina Colon Co. kit (Cat No. MM2041) were used. The kit employs EvaGreen (a fluorescence dye), which emits fluorescence light when it is attached to two-stand DNA. The light is measurable by a PCR device.

The elements of RT-PCR reaction included:

- Pattern sequence (2 μ l);
- Master mix (4 μ l);
- Primer based on the optimum concentration determined in the primary set up tests.
- Deionized distilled water to increase the final volume of the reaction to 20 μ l;

It is notable that reference gene was needed for internal control and 18srRNA was used in this study. After completion of each reaction, the results should be interpreted based on amplification and melt curves. The collected data was analyzed in SPSS (V20) and significance of the results was determined using t-test.

Results

The study was carried out on 30 patients including six women and 24 men. Mean age of the subjects was 48 \pm 10.5 years. 18srRNA gene was used as the reference gene and comparison of mean "ct" values for the center and edges of the legions indicated no significant difference (p-value=0.263), which made the gene suitable as a reference gene.

As to CDH1 gene, there were 12 positive cases out of 30 at the center of lesions (sensitivity = 40%) and 20 positive cases out of 30 at the edges. Comparison of positive CDH1 gene cases at the center and edges of lesions indicated significant differences (P-value<0.001) (Figure 1).

With regard to EGFR gene, there were 19 positive cases out of 30 at the center of lesions (sensitivity = 63.3%) and five positive cases out of 30 at the edges of lesions

Table 1. The Specifications of the Primers Used in RT-PCR Reaction

Parameters	CDH1	EGFR	18s rRNA
F initiator	TGCCATAGATGAATTGAAGGAATG	AAATCCTGCATGGCGCCGTG	GTAACCCGTTGAACCCATT
Length of the primer	24	20	20
R initiator	TGTCATATATTAATTGCATAAACACCTCA	GGTGGTTCTGGAAGTCCATC	CCATCCAATCGGTAGTAGCG
Length of the primer	29	20	20

(control). There was a significant difference between the center and edges of lesions in terms of positive cases of EGFR (p -value<0.001).

Clearly, the rate of a positive CDH1 gene at the edges of lesions was higher than that at the center, while the rate of positive EGFR gene at the center of lesions was higher than that at the edges. In light of this, it must be taken into account that the patients are at high risk of NSCLC, which can be a good guideline for treatments and follow-ups. It is notable that to obtain better results and higher sensitivity, following similar studies, the experiments were carried out with three iterations.

Difference in expression of CDH1 and EGFR genes at the center and edges of lesions

The relative level of difference between the markers was measured for the two groups. This was done through $\Delta\Delta Ct$ for CDH1 and EGFR genes [21]. Value of $\Delta\Delta Ct$ for CDH1 biomarkers was -1.8 and calculating 2 to the power of $-\Delta\Delta Ct$ yields the difference between the markers expressions. The number of primary copies of the markers at the edges of lesions was on average 3.4 times higher

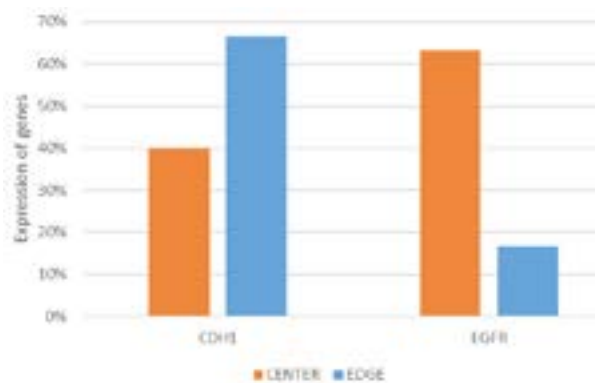


Figure 1. Evaluation of CDH1, EGFR mRNA Expression in the Center and Edges of the Lesions by RT PCR

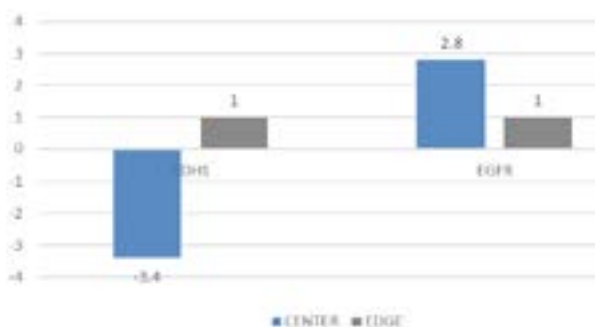


Figure 2. Difference in expression of CDH1 and EGFR genes at the center and edges of lesions

Table 2. Temperature and Term of RT-PCR Reaction

Cycle step	Temperature	Time	Cycles
Initial denaturation	95°C	10 min	1
Denaturation	95°C	10 s	
Annealing	65-60°C	60 s	45
Elongation	72°C	20 s	

than that at the center of lesions.

Value of $\Delta\Delta Ct$ for EGFR was obtained equal to -1.5 and calculating 2 to the power of $-\Delta\Delta Ct$ yields the difference between the markers expressions. The number of the primary copies of the markers at the center of lesions was 2.8 times higher than that of the edges of lesions. Figure 2.

Discussion

Anthracosis or the black disease is the outcome of aggregation of carbon pigments in the bronches, which causes changes in and damages to the bronches that appear as black lesions. These black lesions have been rarely studied by other studies [2].

Although in the industrial countries have managed to decrease the prevalence rate of the disease, it is still highly prevalent in undeveloped countries [22].

Taking into account the growing rate anthracosis in the developing countries and a large number of deaths due to the disease in these countries and given the confirmed relationship between the disease and clinical specifications of different types of lung cancer [4], early diagnosis of the disease of great importance.

The relationship between the black lesions of anthracosis and NSCLC was examined. To this end, the expression of CDH1 and EGFR genes that change in the cancerous conditions was examined [14, 19].

CDH1 molecule (E-cadherin) is an adhesive molecule that plays a role in metastasis and tumor invasion. It is a calcium-dependent molecule that causes inter-cellular adhesion [16]. In most of the cases, epithelial cancerous cells completely or relatively lose their E-cadherin molecule when they start transformation to malignant conditions [16]. This is the case in lung carcinoma and changes in methylation of DNA and histone acetylation ion along with other chromatin-related protein changes can induce epigenetic changes and affect the expression of genes. Therefore, the disruption of gene expression has to do with cancer [23, 24].

By attaching to EGF ligands and TGF, EGFR induces cellular proliferation. Activation of EGFR signaling path in cancerous cells leads to cellular proliferation, angiogenesis, metastasis, and a decrease in apoptosis [19].

Shoji et al., (2006) studied 224 subjects with NSCLC to examine methylation and expression of CDH1 and P16. In general, the improper methylation of the promoter of CPG islands is a major deactivation mechanism of tumor suppressor and tumor dependent genes [25]. They also utilized RT-PCR method for diagnosing and found that the expression of the protein was deactivated through methylation. Thereby, the expression of CDH1 and P16 genes and methylation analysis are highly helpful in the clinical diagnosis of NSCLC. CDH1 gene can be used to diagnose NSCLC.

Lia Yi et al. (2002) studied 42 patients with follicular thyroid cancer and 54 patients with papillary thyroid cancer in terms of E-cadherin expression. Their results showed that the expression of E-cadherin in metastatic papillary cancer was higher than that of the cases without metastasis [26]. To determine the expression of CDH1 they used immunohistochemistry and, consistent with our findings, reported that the positive expression of CDH1 in cancerous tissue decreased with metastasis of lymph glands. Thereby, there is a significant relationship between expression E-cadherin and metastasis to lymph glands. Yango et al. (2012) reported a significant relationship between cancer and the overexpression of EGFR, depth of invasion, and metastasis of lymph glands. They also reported overexpression and high copy number of EGFR gene were commonly observed in NSCLC cases [27]. They used fluorescent in situ hybridization (FISH) to determine EGFR expression. In the present study, the increase of expression EGFR at the center of lesions indicated the oncogenic role of EGFR in NSCLC. Generally, EGFR can be used as a suitable target in cancer treatment.

In conclusion, based on the findings, CDH1 and EGFR biomarkers increased in the black lesions of lung tissue, while the level of EGFR biomarkers in the patient group (center of lesions) was notably higher than that of the control group (normal tissue at the edges of lesions). Moreover, the level of CDH1 biomarkers in the patient's group (center of lesions) was notably higher than that of the control group (normal tissue at the edges of lesions). Thereby, anthracosis patients are at high risk of NSCLC, which is a valuable guideline for treatment and follow up services to the patients.

To have results with higher reliability, future studies need to focus on larger sample groups. In addition, examining other biomarkers in lung cancer can improve the accuracy of a screening test for this type of cancer.

References

1. Talab FR, Akbari H. Relationship between anthracosis and pulmonary tuberculosis in patients examined through bronchoscopy. *Journal of Birjand University of Medical Sciences*. 2007;14(3):9-15.
2. Comert S, Dogan C, Caglayan B, Fidan A, Kiral N, Salepci B. The demographic, clinical, radiographic and bronchoscopic evaluation of anthracosis and Anthracofibrosis cases. *J Pulmonar Respir Med*. 2012;2:119.
3. Castranova V, Porter D, Millecchia L, Ma JY, Hubbs AF, Teass A. Effect of inhaled crystalline silica in a rat model: time course of pulmonary reactions. *Molecular and cellular biochemistry*. 2002;234(1):177-84.
4. Chung MP, Lee KS, Han J, Kim H, Rhee CH, Han YC, et al. Bronchial stenosis due to Anthracofibrosis. *Chest*. 1998;113(2):344-50.
5. Facey K, Bradbury I, Laking G, Payne E. Overview of the clinical effectiveness of positron emission tomography imaging in selected cancers. *HEALTH TECHNOLOGY ASSESSMENT-SOUTHAMPTON-*. 2007;11(44).
6. Gupta GP, Massagué J. Cancer metastasis: building a framework. *Cell*. 2006;127(4):679-95.
7. Jemal A, Siegel R, Ward E, Hao Y, Xu J, Thun MJ. Cancer statistics, 2009. *CA: a cancer journal for clinicians*. 2009;59(4):225-49.
8. Karimi S BN, Sharifi K, Daustany M, Baghbani-Arani F, Kazempour M, et al. Investigating gene expression level of MUC1 and CEA in pleural fluid of NSCLC lung cancer patients with the real-time RT-PCR method. *MINERVA PNEUMOLOGICA*. 2017; 56(1):18-24.
9. Bahrami N GM, Jamaati HR, Mohamadnia A, Dargahi H, Kazempour Dizaji M, Khosravi A, Heshmatnia J, Vahabi P, Bahrami NA. Expression of two essential mRNA biomarker in the peripheral blood as possible biomarkers for diagnosis of non-small cell lung carcinoma. *MINERVA PNEUMOLOGICA*. 2016 55(3):31-6.
10. Sonnenberg P, Murray J, Glynn J, Glyn Thomas R, Godfrey Faussett P, Shearer S. Risk factors for pulmonary disease due to culture-positive *M. tuberculosis* or nontuberculous mycobacteria in South African gold miners. *European Respiratory Journal*. 2000;15(2):291-6.
11. Ghadimi K, Bahrami N, Fathi M, Farzanegan B, Naji T, Emami M, et al. Diagnostic value of LunX mRNA and CEA mRNA expression in pleural fluid of patients with non-small cell lung cancer. *Minerva Pneumologica*. 2017;56:90-5.
12. Karimi S, Mohamadnia A, Nadji SA, Yadegarazari R, Khosravi A, Bahrami N, et al. Expression of two basic mRNA biomarkers in the peripheral blood of patients with non-small cell lung cancer detected by real-time rt-PCR, individually and simultaneously. *Iranian biomedical journal*. 2015;19(1):17.
13. Moshref Behzad N BN, Farzanegan B, Fathi M, Zareh Karizi S, Mohamadnia A. Expression of CK19-mRNA and CEA -mRNA biomarkers in pleural fluid of patients with non-small cell lung cancer. *MINERVA PNEUMOLOGICA*. 2017;56.
14. Downward J, Parker P, Waterfield M. Autophosphorylation sites on the epidermal growth factor receptor. *Nature*. 1984;311(5985):483-5.
15. Lynch TJ, Bell DW, Sordella R, Gurubhagavatula S, Okimoto RA, Brannigan BW, et al. Activating mutations in the epidermal growth factor receptor underlying responsiveness of non-small-cell lung cancer to gefitinib. *New England Journal of Medicine*. 2004;350(21):2129-39.
16. Shigematsu H, Lin L, Takahashi T, Nomura M, Suzuki M, Wistuba II, et al. Clinical and biological features associated with epidermal growth factor receptor gene mutations in lung cancers. *Journal of the National Cancer Institute*. 2005;97(5):339-46.
17. Yan L, Beckman RA. Pharmacogenetics and pharmacogenomics in oncology therapeutic antibody development. *Biotechniques*. 2005;39(4):565-8.
18. Rodríguez PC, Rodríguez G, González G, Lage A. Clinical development and perspectives of CIMAvax EGF, Cuban vaccine for non-small-cell lung cancer therapy. *MEDICC review*. 2010;12(1).
19. Naccache J, Monnet I, Nunes H, Billon-Galland M, Pairen

- J, Guillon F, et al. Anthracofibrosis attributed to mixed mineral dust exposure: report of three cases. *Thorax*. 2008;63(7):655-7.
20. Van den Brande PM, Van de Mierop F, Verbeek EK, Demedts M. Clinical spectrum of endobronchial tuberculosis in elderly patients. *Archives of internal medicine*. 1990;150(10):2105-8.
21. Jamaati H, Bahrami N, Daustany M, Tabarsi P, Farzanegan B, Hashemian SM, et al. Investigating PIK 3 R 3 and ATP2A1 Genes Expressions in Ventilator-Associated Pneumonia Patients Admitted to the Intensive Care Unit of Masih Daneshvari Hospital in 2016. *Reports of Biochemistry and Molecular Biology*. 2018;6(2):118-24.
22. Qorbani M, Yunesian M, Baradaran HR. Indoor smoke exposure and risk of anthracosis. *Iranian journal of medical sciences*. 2014;39(6):571.
23. Liang Z, Zeng X, Gao J, Wu S, Wang P, Shi X, et al. Analysis of EGFR, HER2, and TOP2A gene status and chromosomal polysomy in gastric adenocarcinoma from Chinese patients. *BMC cancer*. 2008;8(1):363.
24. Dicken BJ, Bigam DL, Cass C, Mackey JR, Joy AA, Hamilton SM. Gastric adenocarcinoma: review and considerations for future directions. *Annals of surgery*. 2005;241(1):27.
25. Nakata S, Sugio K, Uramoto H, Oyama T, Hanagiri T, Morita M, et al. The methylation status and protein expression of CDH1, p16INK4A, and fragile histidine triad in nonsmall cell lung carcinoma. *Cancer*. 2006;106(10):2190-9.
26. Liu Y, Jiang C, Tan Y. Pathological study on the expression of cell adhesion molecules and metastasis suppressor gene in thyroid follicular carcinoma and papillary carcinoma. *Zhonghua bing li xue za zhi= Chinese journal of pathology*. 2002;31(4):322-6.
27. Yang Y-L, Xu K-L, Zhou Y, Gao X, Chen L-R. Correlation of epidermal growth factor receptor overexpression with increased epidermal growth factor receptor gene copy number in esophageal squamous cell carcinomas. *Chinese medical journal*. 2012;125(3):450-4.



This work is licensed under a Creative Commons Attribution-Non Commercial 4.0 International License.